



Available online at  
**SciVerse ScienceDirect**  
[www.sciencedirect.com](http://www.sciencedirect.com)

Elsevier Masson France  
**EM|consulte**  
[www.em-consulte.com/en](http://www.em-consulte.com/en)



ORIGINAL ARTICLE

# Reduction plasty for hypertrophic anterior cruciate ligament mucoid degeneration: Clinical and knee laxity outcomes in 23 cases



A. Morice<sup>a</sup>, A. Coupry<sup>a</sup>, F. Lintz<sup>b</sup>, H. Robert<sup>a,\*</sup>

<sup>a</sup> North Mayenne Hospital, Orthopaedic Department, 229, boulevard Paul-Lintier, 53100 Mayenne, France

<sup>b</sup> Clinique de l'Union, boulevard de Ratalaens, BP 24336, 31240 Saint-Jean l'Union cedex, France

Accepted: 18 April 2013

## KEYWORDS

Mucoid degeneration;  
Anterior cruciate  
ligament;  
Knee laxity  
measurement

## Summary

**Introduction:** The best treatment for anterior cruciate ligament (ACL) mucoid degeneration remains open to debate. Current options are total or partial ACL resection, or a more conservative strategy, reduction plasty. The goal of this study was to retrospectively evaluate the effects of reduction plasty for ACL hypertrophy due to mucoid degeneration from clinical outcome and knee laxity points of view.

**Materials and methods:** Arthroscopy was carried out on 23 knees (21 patients) to perform a circular volume reduction plasty of the ACL, while preserving the greatest number of ligament fibers. Notchplasty was not performed. All the patients were seen again with an average follow-up of 32 months (range 8–70).

**Results:** All the knees except three had symmetric postoperative flexion. Three patients still had pain. No patient reported having subjective feelings of instability. Among the 20 knees tested with the GNRB<sup>TM</sup> knee laxity measurement device, one knee had a 2.4 mm difference in laxity and three had between 3 and 4 mm of difference; 16 knees had no residual laxity.

**Discussion:** Treatment of ACL mucoid degeneration by reduction plasty leads to complete pain relief in 80% of cases while maintaining good postoperative knee stability.

**Level of evidence:** Level IV. Retrospective study.

© 2013 Elsevier Masson SAS. All rights reserved.

## Introduction

Mucoid degeneration of the anterior cruciate ligament (ACL) is a benign knee pathology with a frequency of 1.8 to 5.3%

\* Corresponding author.  
E-mail address: [henri.robert@wanadoo.fr](mailto:henri.robert@wanadoo.fr) (H. Robert).

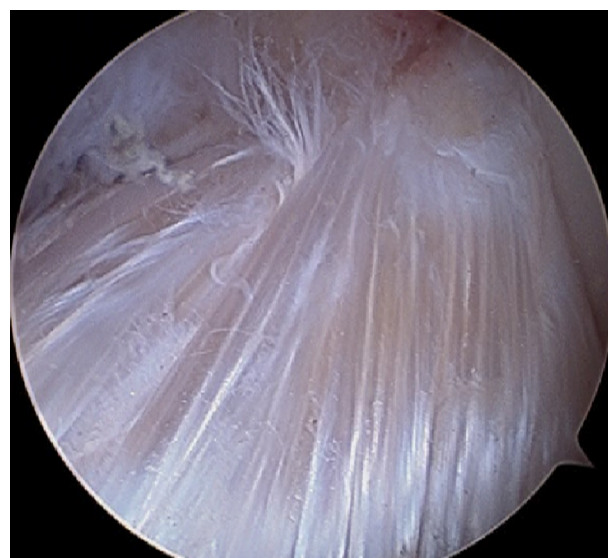[1,2]. Very little information exists about this clinical entity, which was first described in 1999 [3]. ACL mucoïd degeneration is a degenerative disease characterized by diffuse infiltration of a mucoïd substance in the ligament, which differentiates it from cyst-like lesions (synovial and mucoïd cysts). It presents clinically as pain in the popliteal fossa and limited flexion range of motion. The suspected clinical diagnosis can be confirmed by MRI using the criteria described by Bergin et al. [1]: generalized hypersignal of the ACL in T1 and T2, overall increase in the ACL volume, continuous fibers in T2. Further confirmation is provided by histology of intra-operative biopsy samples that show mucoïd (glycosaminoglycan) infiltration of the ACL. No consensus exists as to the appropriate arthroscopic treatment for this condition. Options are periligamentous reduction plasty to restore the original ACL volume, partial resection [4–9], or more commonly, complete ACL resection [10].

The goal of this study was to retrospectively evaluate the effects of reduction plasty for ACL hypertrophy from clinical outcome and knee laxity points of view. The reduction plasty technique used in this study aimed to return the ACL back to its original volume, a notable difference relative to previously mentioned resection techniques. We hypothesized that volume reduction plasty would be as effective in treating pain and flexion limitations as ACL resection (partial or total), without causing symptomatic residual knee laxity.

## Patients and methods

This was a single-center, single-surgeon (HR), retrospective study of 23 knees in 21 patients (two patients had bilateral involvement). There were 17 men and four women (sex ratio 0.85) and the average age was 50.4 years (range 31–70) at the time of the procedure. Patients were operated on between December 2005 and June 2012. Patients were included if they were symptomatic (flexion limitation and/or pain) and presented with the hypertrophic form of ACL mucoïd degeneration based on MRI criteria [1]. Patients were excluded if they had cyst-like lesions or the atrophic form of ACL mucoïd degeneration. The clinical and radiological features of these patients are presented in [Supplementary data, Appendix 1](#). Seven of the patients were recreational athletes before symptoms started, but none at a high level. Twenty-two of the 23 knees had an average flexion deficit of 19° (range 10–50°), relative to the contralateral knee; average knee flexion amplitude was 118° (range 80–135°). Before the surgery, none of the patients complained of instability and no anterior laxity was detected through clinical testing or with a knee arthrometer (GNRB™, Laval, France). Four patients had a previous medial meniscectomy and one had a lateral meniscectomy.

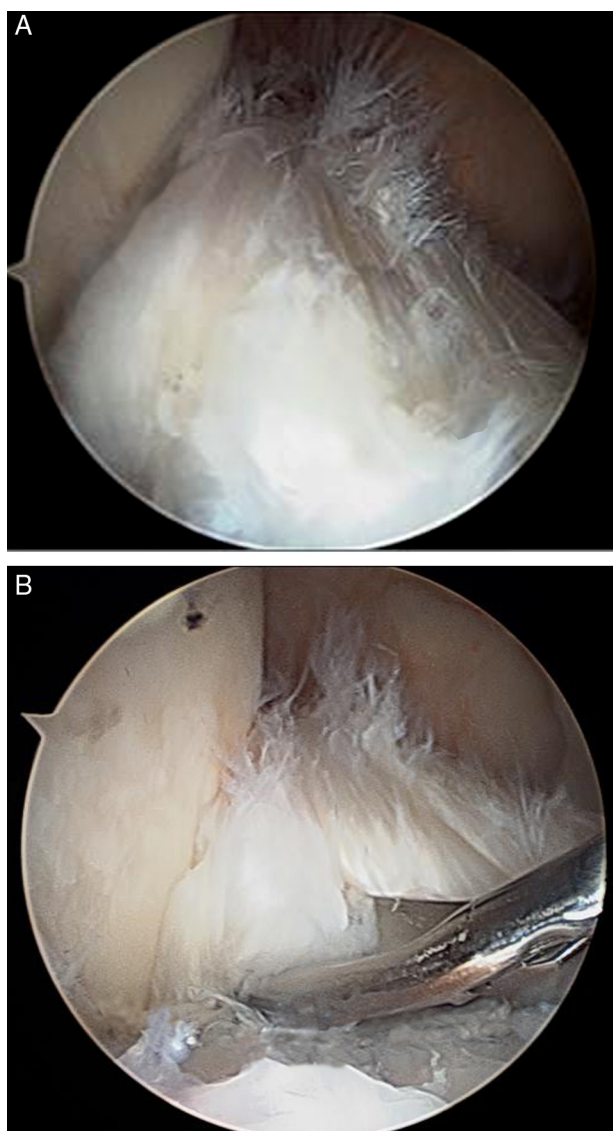
All patients underwent a knee MRI to confirm the diagnosis; in six cases, the radiologist found a chronic ACL tear. Bone lesions were found in five cases: three with femoral condyle bone cysts on the axial face of the lateral condyle and two with tibial cysts under the intercondylar eminence. MRI sagittal slices were used to calculate the sagittal notch angle (SNA); frontal slices were used to calculate the ratio between the width of the ACL and width of the notch (Intercondylar Notch Index) [9].



**Figure 1** Arthroscopy view of ACL mucoïd degeneration in the left knee. The hypertrophied ACL fills the entire notch, the synovial membrane is missing, but the fibers are continuous.

All patients were operated on an out-patient basis. Arthroscopy was performed with a tourniquet through two portals: anteromedial for the instrumentation and anterolateral for the 30° scope. The diagnosis was confirmed by the presence of an ACL that was hypertrophic, bulging into the notch, yellowish in color, hard when probed with hook and that still had continuous fibers. The synovial membrane was absent or atrophied in most cases ([Fig. 1](#)). These observations were consistent with the diagnostic criteria used by McIntyre et al. [11]. The amount of bulging on the anterior, medial or lateral sides was noted and used to guide the volume reduction procedure. In one patient, only the anteromedial bundle was affected ([Fig. 2](#)); in all the other patients, both bundles were affected. The following meniscus injuries were also found during the arthroscopy (61% of patients): six cases of medial degeneration, one case of lateral degeneration, two cases with medial and lateral degeneration and five cases of isolated meniscus injury. Three patients had a partial meniscectomy during the arthroscopy procedure because their meniscal tear was deemed symptomatic.

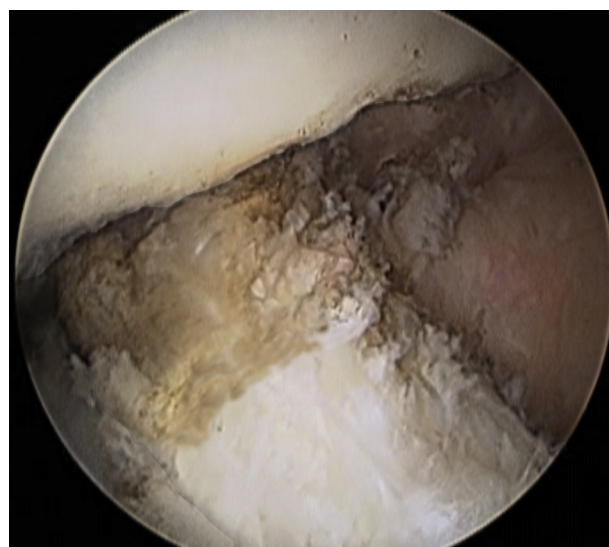
The arthroscopy treatment consisted of ACL reduction plasty by circular debridement using a radiofrequency ablation (RFA) probe to reduce the volume of the hypertrophied ACL. The debridement started on the anterior side and was then taken medially, laterally and posteriorly. The probe swept across the abnormal area from top to bottom, while focusing on the areas with the largest bulges. The goal was to return the ACL to its original volume while also removing any lateral or superior impingement with the notch during extension and with the posterior cruciate ligament. This volume reduction recreated the space between the two cruciate ligaments and joined the pre- and retro-ligamentous spaces. The plasty procedure focused on the peripheral aspect of the ACL, without trying to remove any of the intra-ligamentous mucoïd substance. The volume reduction stopped once the impingement had been removed. As many ligament fibers as possible were preserved ([Fig. 3](#)).



**Figure 2** Partial form of ACL mucoid degeneration. Only the anteromedial bundle is affected (A); resection of the hypertrophied area with basket forceps (B).

The patients were allowed to bear weight on their leg and freely move their joint after the procedure. Patients having problems with recovery were provided with rehabilitation sessions once the sutures had been removed.

The evaluation at the latest follow-up sought to uncover any residual pain, asymmetry in full flexion (measured by goniometer) and instability. The KOOS and IKDC functional scores were used in the postoperative assessments. The residual laxity was evaluated with the knee arthrometer at 134N [12,13]. If the difference in the knee laxity between preoperative and postoperative measurements was greater than 3 mm, the functional loss was considered complete; if it was greater than 1.5 mm but less than 3 mm, the loss was partial. The ACL was considered normal if the difference in laxity was less than 1.5 mm. The elasticity slope was measured and the difference between preoperative and postoperative values calculated. If the difference in slope was less than  $12 \mu\text{m}/\text{N}$  and the difference in laxity was



**Figure 3** Appearance of ACL after circular reduction plasty: normal ACL volume is restored and impingement no longer exists, even without a notchplasty.

between 1.5 and 3 mm, there was a partial loss in continuity. If the difference in slope was greater than  $12 \mu\text{m}/\text{N}$  and the difference in laxity was greater than 3 mm, there was a complete tear [14].

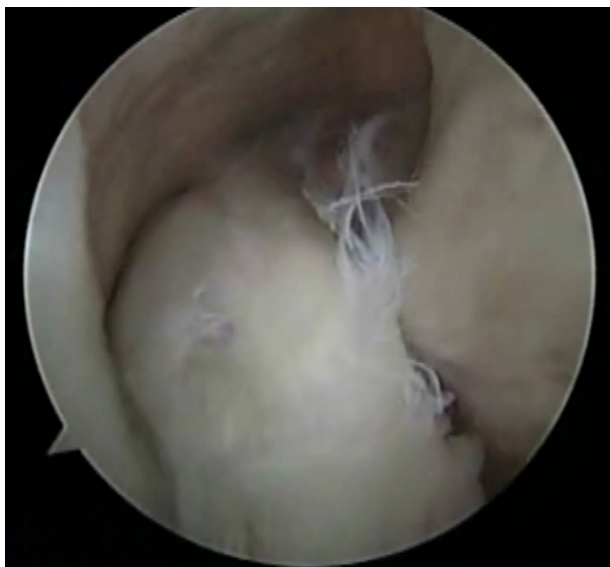A paired Student's T-test was used to compare preoperative and postoperative knee flexion values with SSPS® software. Data for the SNA and ACL Notch Index were compared to published historical data [9] using a T-test.

## Results

All the patients were evaluated by an independent examiner (AM or AC) who had not been involved in the surgical procedures. The average follow-up was 32 months (range 8 to 70), with a median of 24 months.

No local or systemic complications were noted. The pain was completely gone in 20 of the 21 patients (within two months in 15 cases). One patient with both ACL mucoid degeneration and trochlear dysplasia did not get any pain relief from the initial procedure and was operated a second time for the dysplasia. All but three patients regained the same range of motion as the contralateral knee. Flexion had increased by  $18.5^\circ$  (range  $10-40^\circ$ ) ( $P=0.03$ ) on average. The average IKDC score was 81 (range 45–97); the average KOOS score was 88 (range 56–99); the average KOOS pain score was 90 (range 60–100). All the patients who were recreational athletes before the procedure were able to return to their sport.

None of the patients reported any subjective episodes of instability. Nineteen of the knees were stable when tested clinically. One patient had a delayed hard endpoint and three patients had a soft endpoint. One patient had a moderate pivot shift sign. None of the patients required an ACL reconstruction. Twenty of the knees were tested on the GNRB™ knee arthrometer; the three other knees could not be tested because of technical issues. No postoperative laxity was found in 16 of the knees (average difference of 0.7 mm). Four knees had an abnormal difference in laxity:



**Figure 4** Visualization by arthroscopy one year after resection plasty for diffuse ACL mucoïd degeneration; the ACL has returned to its normal volume.

one knee had evidence of a partial tear (laxity difference of 2.4 mm, slope difference of  $10 \mu/N$ ); three knees had evidence of a complete tear (difference of 3.4 mm, 3.5 mm and 3.8 mm, respectively, with the slope difference being above  $12 \mu/N$  in all cases).

One patient had another arthroscopy one year later for symptoms of a medial meniscus tear. The ACL appeared well restored with a synovial membrane of normal thickness, no impingement with the notch and good fiber tension found when using a hook probe and the GNRB™ arthrometer (Fig. 4).

Based on the MRI, the average sagittal notch angle (SNA) was  $35.4^\circ$  (range  $32-44^\circ$ ) and the average ACL Notch Index was 0.56 (range 0.44-0.77).

## Discussion

Conservative treatment through circular volume reduction of the hypertrophic form of ACL mucoïd degeneration was effective in reducing pain and restoring lost flexion amplitude. This is a simple treatment that provides good functional recovery and is performed on an out-patient basis. Since most of the ACL is preserved, even if infiltrated by mucoïd substance, the knee is still clinically stable. No recurrence of the clinical signs was found at an average follow-up of 32 months. This treatment modality does not apply to atrophic forms of ACL mucoïd degeneration, which seem to be rarer.

The persistence of knee pain in two patients (other than patellofemoral dysplasia) suggests that the associated tibiofemoral lesions may also play a part. In the current study, 61% of patients had meniscal tears and/or degenerative changes in their condyles. Kim et al. had found associated lesions in nearly 95% of cases [5].

The four cases of postoperative laxity (between 2 and 4 mm) in the current study suggest that the ligament

became more fragile either because of the intrinsic mucoïd infiltration or due to overly aggressive debridement. It is difficult to determine the right amount of volume to remove during the surgery. The RFA probe must be used with care because of the risk of deep burns, which would become apparent later on. In some patients with a wider notch (high ACL Notch Index), the ACL reduction plasty excessively reduced the final size of the ACL – to less than the original ACL size – which probably explains why the difference in laxity was greater than 3 mm. The GNRB™ is very precise and sensitive for detecting partial ACL tears [13]. In one study of 27 patients (29 knees) treated with resection, the rate of postoperative laxity was 93% (laxity difference of 5 to 8 mm on Telos™), with two patients requiring subsequent ligament reconstruction [10]. Rolf and Watson reported secondary instability 14 weeks after the surgery [15]. McIntyre et al. reported one case of non-traumatic instability out of 10 knees, one year after the surgery [11]. Nishimori et al. recommended systematic ACL reconstruction in younger patients [8].

The conservative treatment proposed in the current study must be differentiated from partial resection, which could remove half of the ACL [10]. The lack of pain recurrence provides further support for the “minimalist” plasty procedure proposed here. Many studies advocate the use of partial resection [4–6,8,9]. The results are similar to the ones reported in the current study in terms of pain reduction, but occasionally the ACL had to be reconstructed because of residual laxity [10,16,17]. Others advocate complete ACL resection [10].

In some cases, ACL debridement is combined with a notchplasty [4,5,17]. The latter procedure is not essential in our opinion, since the notch impingement no longer exists after the ligament volume is reduced. Our study also confirms the role of a narrower and more vertical notch in the etiology of the pathology. The measured sagittal notch angle (SNA) of  $35.4^\circ$  ( $32-44^\circ$ ) was less than in historical data with normal knees ( $39.1 \pm 4^\circ$ ); the ACL Notch Index was higher in the current study (average 0.56; range 0.44–0.77) than in normal knees ( $0.26 \pm 0.04$ ) [9]. Other studies have also implicated the notch [9]. These elements reinforce the hypothesis that microtrauma leads to mucoïd degeneration of the ACL, since the ACL impinges with the notch repeatedly during extension movements. A recent study also established the relationship between greater tibial posterior slope and ACL mucoïd degeneration [18].

The main limitation of the current study was the lack of a control group undergoing complete ACL resection, to which the clinical and knee laxity results could have been compared. A randomized study comparing these two surgical strategies should be performed in the future.

## Conclusion

Circular volume reduction plasty for the hypertrophic form of ACL mucoïd degeneration led to good subjective and functional results, while preserving the ACL’s stabilization function and avoiding the need for secondary surgery.

## Disclosure of interest

The authors declare that they have no conflicts of interest concerning this article.

## Appendix A. Supplementary data

Supplementary data (Appendix 1) associated with this article can be found, in the online version, at <http://dx.doi.org/10.1016/j.otsr.2013.04.010>.

## References

- [1] Bergin D, Morisson WB, Carrino JA, Nallamshetty SN, Bartolozzi AR. Anterior cruciate ligament ganglia and mucoïd degeneration: coexistence and clinical correlation. *Am J Roentgenol* 2004;182:1283–7.
- [2] Salvati F, Rossi F, Limbucci N, Pistoia ML, Barile A, Masciocchi C. Mucoïd metaplastic-degeneration of anterior cruciate ligament. *J Sports Med Phys Fitness* 2008;48:483–7.
- [3] Kumar A, Bickerstaff DR, Grimwood JS, Suvarna SK. Mucoïd cystic degeneration of the cruciate ligament. *J Bone Joint Surg Br* 1999;81:304–5.
- [4] Narvekar A, Gajjar S. Mucoïd degeneration of the anterior cruciate ligament. *Arthroscopy* 2004;20:141–6.
- [5] Kim TH, Lee DH, Lee SH, Kim JM, Kim CW, Bin SI. Arthroscopic treatment of mucoïd hypertrophy of the anterior cruciate ligament. *Arthroscopy* 2008;24:642–9.
- [6] Makino A, Pascualk-Garrido C, Rolon A, Isola M, Musculo DL. Mucoïd degeneration of the anterior cruciate ligament: MRI, clinical, intraoperative, and histological findings. *Knee Surg Sports Traumatol Arthrosc* 2011;19:408–11.
- [7] Motmans R, Verheyden F. Mucoïd degeneration of the anterior cruciate ligament. *Knee Surg Sports Traumatol Arthrosc* 2009;17:737–40.
- [8] Nishimori M, Sumen Y, Sakaridani K. Mucoïd degeneration of the anterior cruciate ligament—a report of two cases. *Magn Reson Imaging* 2004;22:1325–8.
- [9] Cha JH, Lee SH, Shin MJ, Choi BK, Bin SI. Relationship between mucoïd hypertrophy of the anterior cruciate ligament and morphological change of the intercondylar notch: MRI and arthroscopy correlation. *Skeletal Radiol* 2008;37(9):821–6.
- [10] Lintz F, Pujol N, Dejour D, Boisrenoult P, Beaufils P. Anterior cruciate ligament mucoïd degeneration: selecting the best treatment option. *Orthop Traumatol Sug Res* 2010;96:400–6.
- [11] McIntyre J, Moelleken S, Tirman P. Mucoïd degeneration of the anterior cruciate ligament mistaken for ligamentous tears. *Skeletal Radiol* 2001;30:312–5.
- [12] Robert H, Nouveau S, Gageot S, Gagnière B. Nouveau système de mesure des laxités sagittales du genou, le GNRB®. Application aux ruptures complètes et incomplètes du LCA. *Orthop Traumatol Surg Res* 2009;95:171–6.
- [13] Lefevre N, Bohu Y, Naouri JF, Klouche S, Herman S. Validity of GNRB® arthrometer compared to Telos in the assessment of partial ACL tears. *Knee Surg Sports Traumatol Arthrosc* 2013, <http://dx.doi.org/10.1007/s00167-013-2384-4> [Epub].
- [14] Robert H, Nouveau S, Gageot S, Gagnière B. Can you detect partial ACL tears with GNRB? 2010.
- [15] Rolf C, Watson TP. Case report: intra tendinous ganglion of the anterior cruciate ligament in a young footballer. *J Orthop Surg* 2006;1:11.
- [16] Lintz F, Pujol N, Boisrenoult P, Bargoin K, Beaufils P, Dejour D. Anterior cruciate ligament mucoïd degeneration: a review of the literature and management guidelines. *Knee Surg Sports Traumatol Arthrosc* 2011;19:1326–33.
- [17] Chudasama CH, Chudasama VC, Prabhakar MM. Arthroscopic management of mucoïd degeneration of ACL. *Indian J Orthop* 2012;46:561–5.
- [18] Jung KWJ, Cho SD, Park KB, Youm YS. Relation between mucoïd degeneration of the ACL and the posterior tibial slope. *Arthroscopy* 2012;28:502–6.